

Revision of amputation stumps in Dodoma — Tanzania

A. LORO, F. FRANCESCHI, and J. M. SAMWEL

Dodoma Regional Hospital, Tanzania

Abstract

The records of Dodoma Orthopaedic Department, Tanzania were reviewed for the period July 1986 to December 1990 in order to identify the reasons for revision surgery. A total of 26 patients required revision surgery. Two main groups were identified. In the first group 4 patients had a higher level of amputation because of gangrene. In the second group 22 patients had revision surgery because of other stump defects caused by technical mistakes when carrying out the original amputation, or other complications.

Introduction

An amputation is not a final act in itself, but a prelude to the long rehabilitation process that aims to overcome the disability of limb loss. The surgeon should prepare a stump that is suitable for limb fitting, as part of the rehabilitation process.

The records of Dodoma General Orthopaedic Department from July 1986 to December 1990 have been reviewed in order to identify the reasons for revision surgery. The series includes cases where the initial amputation was carried out in the Dodoma Orthopaedic Department, and also patients referred from other centres to its Orthopaedic Workshop for limb fitting.

Table 1 shows the total number of limb amputations that have been carried out, during the period under review, at Dodoma Orthopaedic Department which is one of the three Orthopaedic Centres in the country.

All correspondence to be addressed to F. Franceschi, Orthopaedic Dept., Dodoma Regional Hospital, P.O. Box 1124, Dodoma, Tanzania.

Dodoma Orthopaedic Workshop is one among the seven workshops that are currently operating in Tanzania and it cares for the population of its central zone. It was established in 1985, with the financial assistance of the Italian Government channelled through an Italian non-Governmental Organisation, C.U.A.M.M. of Padova.

Material and methods

In the period surveyed 26 patients had revisions of the amputation stump, 21 males and 5 females with a mean age of 33, and an age spread from 9 years to 65 years of age.

Thirty operations were performed on 29 stumps; 3 were bilateral amputees, and 1 patient was revised twice. Of the 30 operations, 27 were on the lower limbs; 16 stumps on the left and 13 on the right.

Ten patients came from the Dodoma Orthopaedic Department, 2 from another Orthopaedic Centre, 11 from other Regional Hospitals and 3 from District Hospitals.

The initial amputation had been carried out for road traffic accidents in 10 cases, train accidents in 2, work accidents in 2, 3 for tropical ulcers, 2 for complications after compound fractures, and 3 for wet gangrene. Leprosy, snake bite, too tight a plaster cast and ergot

Table 1. Number of limb amputations by year in Dodoma Regional Hospital.

1986 (2nd semester)	12
1987	34
1988	29
1989	21
1990	27
	Total 123

Table 2. Cause of first amputation in revised patients.

Road accidents	10
Train accidents	2
Work accidents	2
Tropical ulcer	3
Wet gangrene	3
Complications after compound fracture	2
Leprosy	1
Snake bite	1
Tight POP	1
Ergot intoxication	1
Total 26	

intoxication account for the remainder (Table 2).

It has been possible to distinguish two main groups.

The first group of 4 patients had a higher level of amputation because of gangrene of the stump. In this group, 3 had revisions a matter of days after the initial amputation because of gangrene of the flaps. The fourth patient developed gross infection and wound breakdown of his through-knee amputation flaps.

The second group of 22 patients had revision surgery because of other stump defects, caused by technical mistakes when carrying out the original amputation or because of complications. It included inadequate stump length, deformed or misshapen stumps, chronic bone and soft tissue infection and overgrowth of the bone of the stump.

Discussion

Because of restricted means and lack of investigative facilities, amputation levels are decided on purely clinical grounds. In those patients that developed gangrene of the stump, there had been an effort to retain the knee joint, but the selected level was too low. More than 120 lower limb amputations were carried out in the period under review and because of the importance of knee retention the failure rate (3 cases) was regarded as acceptable.

Stump revision to obtain an adequate amputation stump for limb fitting was the principal reason for revision in the series. There is close co-operation between the Orthopaedic Department and the Orthopaedic Technologist in the Orthopaedic Workshop, who referred patients with stumps that gave rise to difficulties.

Poorly formed amputation stumps, including inadequate muscle cover have been responsible for most of the revisions. There would seem to have been an inadequate myodesis, and in delayed suture an inadequate prediction of the level of muscle retraction. Suture of the skin without myodesis resulted in painful subcutaneous bone. In 5 below-knee amputees, the tibial crest at the bone section had not been bevelled, resulting in a painful stump. One above-knee amputee had revision because of redundant fatty skin cover.

Different procedures, including bone shortening, myodesis and soft tissue shaping were utilised in the revisions. The main problems were:

Muscle cover

It would appear that at the initial amputation, inadequate muscle flaps were left, especially in delayed suture which resulted in retraction of the muscles.

This meant that the level of bone section was left too distal. These factors resulted in subcutaneous terminal bone, which caused difficulty in prosthetic fitting. An inadequately covered stump may produce socket sores (Fig. 1).

Stump length

Five below-knee stumps were revised because they were too long, and 2 too short for prosthetic fitting. This resulted from inadequate level selection. There was one below-knee 8 cm stump, which took a year to

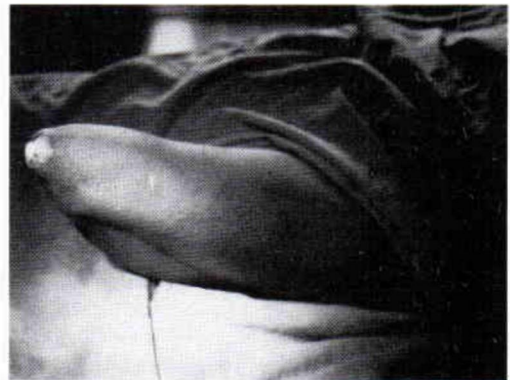

Fig. 1. An above-knee stump for which a procedure of revision has been necessary. The patient was amputated for a long standing leprotic ulcer of his foot. The possibility to perform a through-knee amputation has been overlooked.

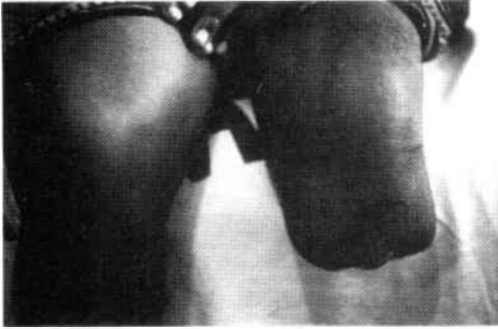

Fig. 2. A short below-knee stump. A through-knee amputation has been found necessary for successful limb fitting.

heal before referral, and which proved too short to be fitted (Fig. 2). If the below-knee stump is short, excision of the fibula is strongly advocated. The possibility of performing a through-knee amputation also has to be considered, instead of struggling with a short below-knee stump that is inadequate for the task. Too short a stump produces a short lever that is inadequate to control the prosthesis, requiring excessive energy and resulting in high local pressures. A below-knee stump which is too long is liable to fracture if the patient falls, and atrophy of the muscles results in an ill padded stump that causes fitting difficulties, and inadequate terminal cover (Fig. 3).

Infection

Nine stumps were revised because of persistent bone or soft tissue infection. Four

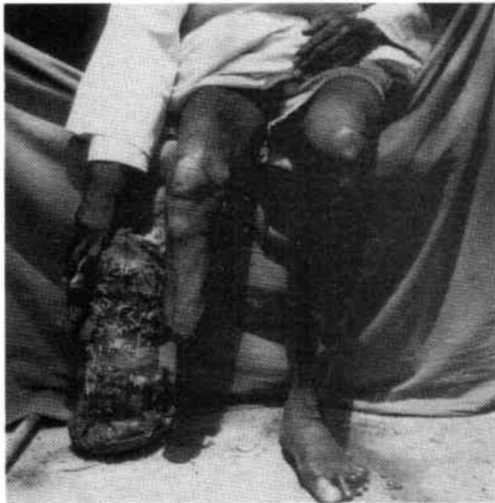

Fig. 3. An excessively long below-knee stump is going to become, in the long run, a frustum of cone unfit for a prosthesis, due to severe atrophy of the muscles.

had osteomyelitis, and sequestrectomy and adequate drainage resulted in healing. Delayed closure of the wound might have allowed the infection to settle down (Figs. 4 and 5).

Five stumps had soft tissue infection. The removal of silk sutures used to tie the blood vessels resulted in sound healing. The use of silk ligatures in a potentially infected wound is not recommended.

Bone overgrowth

Two revisions in the same 9 year old child were carried out for stump overgrowth.

Training

It would be helpful if the surgeon tailored the amputation stumps to the needs of the prosthetist rather than expecting the prosthetist to adapt his socket to any stump produced. Apart from there being bio-mechanical reasons for prescribing amputations at selected levels, the range of artificial limbs produced by prosthetists in developing countries is limited by working conditions and available

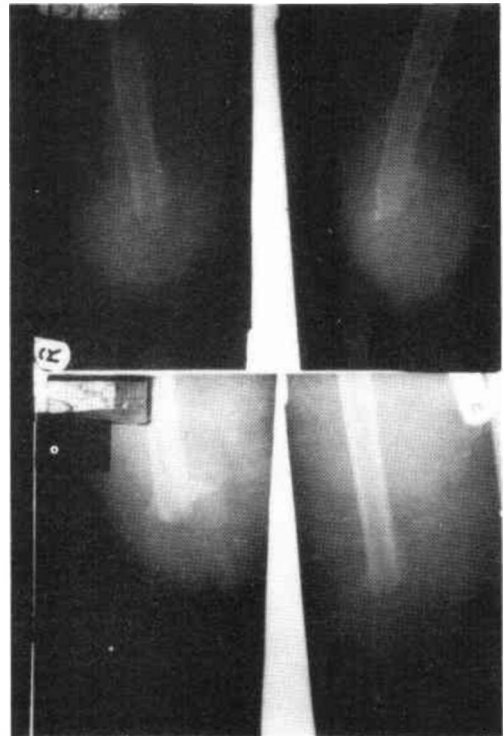


Fig. 4. Chronic osteomyelitis of an above-knee femoral stump. Two small sequestra, visible in the top films, have been removed, as can be seen in the post-operative x-rays.

technology. It would thus seem that a knowledge of prosthetics is a requirement in the training of a surgeon who might perform amputations.

Working conditions, sterility in operating theatres and the existing infection of many of the wounds imposes problems. In the case of gangrene many amputations need delayed suture, with delayed fabrication of the stump. At the time of final closure, it is not merely a question of covering the bone, but fashioning suitable muscle and skin flaps.

REFERENCES

- BOHNE WHO (1986). *Atlas of Amputation Surgery*. — New York: Thieme Med Pub.
- WATERS RL, PERRY J, ANTONELLI DE (1976). Energy cost of walking in amputees: influence of level amputation. *J Bone Joint Surg* **58A**, 42–46.
- LORO A, FRANCESCHI F, MOSHA ECP, SAMWEL J (1990). A survey of amputations at Dodoma Regional Hospital, Tanzania. *Prosthet Orthot Int* **14**, 71–74.
- BAUMGARTNER R, LANGLOTZ M (1980). Amputee stump radiology. *Prosthet Orthot Int* **4**, 97–100.

Fig. 5. (Top) The film shows the presence of a big sequestrum near the bone end in this above-knee stump N4. (Bottom) After surgical removal the sequestrum was probably a fragment of a severely comminuted fracture which has been left in situ at the time of first operation performed following a motor accident.