

Prostheses to Achieve Independent Ambulation for a Geriatric Quadruple Amputee

by Gustav Rubin, M.D., FACS
Fred Harris, B.S., C.O.

The elderly quadruple amputee presents a challenge to a prosthetic clinic team. Although this problem is occasionally noted in children with congenital amputations,^{1,2} it is much less commonly encountered in adults. During the past fifteen years there has been only one other total quadruple amputee—a young adult who was treated at our center and did not wish to have his case published.

Here we have the opportunity to present a report on the prosthetic fitting of a 64 year old veteran who was referred to our Special Clinic Team in 1981, from the VA Medical Center in Cleveland, Ohio, with a history of quadruple amputations secondary to frost bite.

H.F. was found on January 8, 1981, on a cold winter day, lying outside his home. He was unresponsive and had a rectal temperature of 77°. After a period of conservative care, amputations on all four limbs were done on February 4, 1981, at the private hospital in Canton, Ohio, to which he had been initially taken. The surgery resulted in a right wrist disarticulation, a left distal forearm amputation just proximal to the carpus, and bilateral below-knee amputations. The residual limbs healed without complications and the patient was transferred, on March 11, 1981, to the V.A. Medical Center in Cleveland, Ohio, where he was started on a course of physical and corrective therapy, including daily strengthening exercises to all four extremities.

He was considered highly motivated and an "excellent candidate" for prostheses. He was referred to our center, which was then the V.A. Prosthetics Center, and was examined by the Special Prosthetic Clinic Team on May 21, 1981.

H.F. also had a background history of gastrointestinal surgery ten years earlier for a perforated peptic ulcer. The report of the physical examination at the hospital prior to referral for prosthetic prescription revealed a normal cardiovascular examination, a blood pressure of 110/70, but a liver enlarged three cm. below the costal margin. The popliteal pulses were good.

The evaluation by the clinic team confirmed that H.F. was well-motivated. He was an intelligent, cooperative, slender individual, whose amputations were all well-healed. The right below-knee residual limb measured 4 inches to the bone end and the left below-knee limb measured 4½ inches to the bone end. There were mild knee flexion contractures which were not considered fitting problems. On the right below-knee limb there was a palpable, slight, irregular, distal anterior tibial bone prominence, unattached to the overlying tissues. On the left side the below-knee limb was poorly padded by soft tissue. As the examiner attempted to mimic piston motion of the soft tissue sleeve by drawing the soft tissue proximally, the distal skin, overlying a slight bone irregularity, blanched. X-rays of the left below-knee residual limb confirmed the clinical impression of bone irregularity and x-rays of the upper extremities confirmed the right true wrist disarticulation and the left amputation just proximal to the carpus at the level of the distal radius and ulna.

The amputee had been through a great deal (Figure 1) prior to referral to the Clinic Team and it was the consensus, at this time, that referral for a lower extremity revision would have adverse impact on his motivation. It was

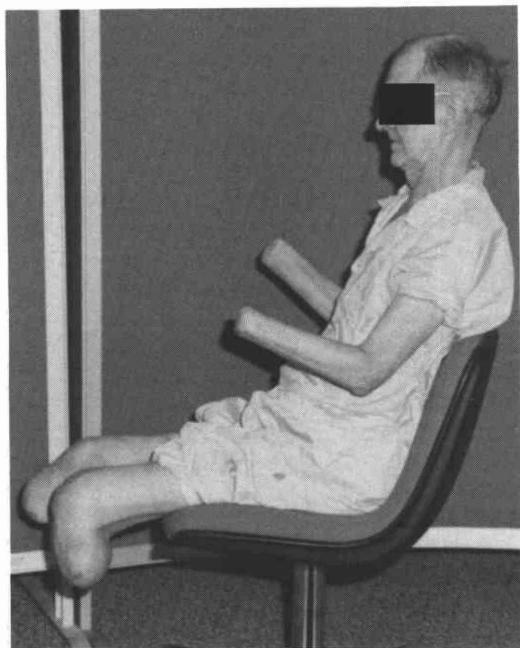


Figure 1. H.F., a 64 year old veteran and quadruple amputee.

the aim of the staff to make the patient as independent as possible by adapting the prostheses to his donning and doffing capabilities. PTS prostheses were prescribed to be fabricated with loops on the soft socket inserts (Figure 2) to aid donning. The prostheses for the upper extremities employed a Northwestern ring for the figure of eight harness, double wall sockets, friction wrists, and Dorrance Lyre hooks.

In addition, he was prescribed for platform crutches, which were modified with distal rings for the hooks and forearm loops (Figure 3). The forearm loops had to be pre-adjusted into a fixed position so that H.F. could slip the prostheses through the loops and avoid the need for repeatedly adjusting the Velcro® straps.

On June 11, 1981, fabrication of the below-knee prostheses was completed and the amputee demonstrated that he could stand and take several steps in parallel bars with assistance on each side. An exercise and training program with the prostheses was outlined at the hospital. The instructions included careful monitoring of the stumps during this time.

On June 18, 1981, the amputee was observed to be doing "extremely well," as indi-

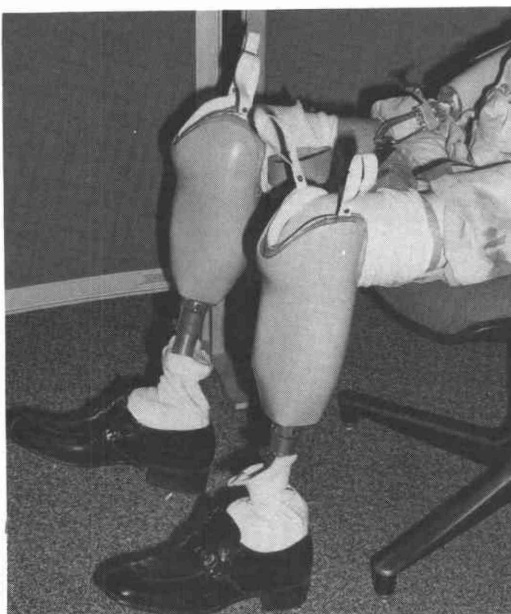


Figure 2. Below-knee prostheses were adapted with loops on the soft socket inserts to aid in donning.

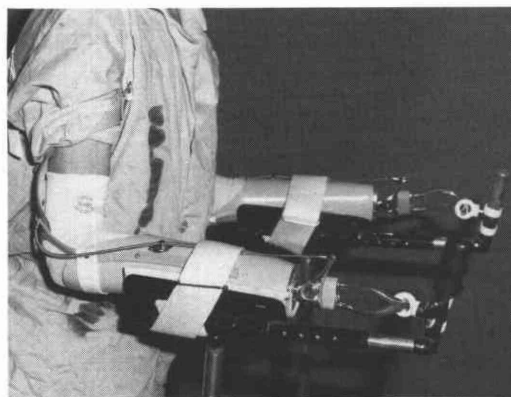


Figure 3. Platform crutches were also modified with distal rings for the hooks and forearm loops.

cated by the clinic team's notes. By this time he had also been fitted with his upper extremity prostheses and forearm crutches. He rapidly progressed to unassisted ambulation with crutches (Figure 4).

When seen by the clinic team on August 10, 1981, H.F. walked with the aid of a platform crutch. Because of irritation over the right ulnar styloid process, which was unresponsive to modification of the socket, a new socket was

